



Trade Science Inc.

ISSN : 0974 - 7532

Volume 6 Issue 2

Research & Reviews in

BioSciences

Short Communication

RRBS, 6(2), 2012 [41-43]

Clinical-hematological profile of Indian hemoglobin sickle cell D Punjab patients

S.Pandey¹, R.Ranjan¹, T.Seth¹, V.Shah², R.M.Mishra³, S.W.Pandey¹, R.Saxena^{1*}

¹Department of Hematology, AIIMS, New Delhi, (INDIA)

²Department of Cardiac Biochemistry, AIIMS, New Delhi, (INDIA)

³Department of Environmental Biology, APS University Rewa, (INDIA)

E-mail: reusax@hotmail.com

Received: 5th December, 2011 ; Accepted: 22nd December, 2011

ABSTRACT

Hb D heterozygous is a clinically silent condition, but co-inheritance of Hb D with Hb S or beta thalassemia produces clinically significant conditions like sickle cell anemia and chronic hemolytic anemia of moderate severity. Complete blood count and red cell indices were measured by automated cell analyzer. Quantitative assessment of hemoglobin Hb F, Hb A, Hb A₂, HbS and Hb D was performed by high performance liquid chromatography (HPLC) DNA extraction done by phenol-chloroform method. Molecular study for common alpha deletions were done by Gap-PCR. Patients with Hemoglobin S-D disease were show the severity of the disease. These patients had sickle crises and moderate hemolytic anemia. Frequency of anemia (84.61%), Splenomegaly (61.53%) and Jaundice (44.15%) were high in the HbSD patient. 38.46% patients were transfusion dependent. HbS-D patients red cell indices were suggestive like sickle cell anemia patients while their clinically behavior showed a degree of variability.

© 2012 Trade Science Inc. - INDIA

KEYWORDS

Hemoglobinopathies;
High performance of liquid chromatography;
Haemoglobin D.

INTRODUCTION

Hemoglobin (Hb) D hemoglobinopathy is a predominant disease in north-west India and usually presents with mild hemolytic anemia and mild to moderate splenomegaly. Heterozygous form of Hb D is clinically silent, but co-inheritance of Hb D with Hb S or beta-thalassemia produces clinically significant conditions like thalassemia intermedia of moderate severity. Both Hbs S and D are asymptomatic when present as traits^[1,2]. In homozygous form Hb D is almost always asymptomatic^[3] and double heterozygosity of HbD and HbS

is associated with moderately severe haemolytic anaemia with crisis^[4,5]. There are several HbD of which only HbD Punjab (B121 Glu-Glu) interacts with HbS to form a clinically significant condition^[3,4]. This is ascribed to a specific interaction in the fiber due to a possible role of residue 121 in beta chain in stabilising the polymer and thus increasing intracellular polymerization of HbS^[6]. Thus abnormal haemoglobins resulting from substitution at position 121 of the beta globin chain when co inherited with HbS enhance the sickling phenomenon^[7]. Average gene frequency of HbD has been observed to be 0.86% with a higher frequency of 3.6% seen in

Short Communication

Punjab followed by Jammu and Kashmir (3.3%) and Uttar Pradesh (2.3%)^[8]. There is a lack of data for compound heterozygosity of HbS-D and clinical variability of patient in India; thus our aim was to determine the clinical and hematological profile of Indian HbS-D patients.

MATERIAL AND METHOD

Subject of HbS-D were recruited; the patients attending the laboratory between three year for routine check-up. About 5 ml blood sample collected from patients after taken informed consent and study was approved by institutional ethical committee. All the investigation were done in the department of hematology All India Institute of Medical Sciences New Delhi. Complete blood count and red cell indices were measured by automated cell analyzer (SYSMEX K-4500, Kobe Japan). Giemsa-stained peripheral blood smears were examined for red cell morphology. Quantitative assessment of hemoglobin HbF, HbA, HbA₂, HbS and HbD was performed by high performance liquid chromatography (HPLC-Bio-Rad-Variant™ Bio Rad, CA, USA). DNA extraction was done by phenol-chloroform method. Alpha deletions studies were done by PCR according to published literature^[9-11]. Mean value, standard deviation & frequency distribution were used to evaluate the hematological & clinical data.

RESULT AND DISCUSSION

Thirteen haemoglobin sickle cell D (9 male and 4 female with mean age 6.13±4.21) patient were characterized. All patients were symptomatic and their peripheral smears showed microcytic hypochromic red cells with few target and sickle cells. Anemia (84.61%), Splenomegaly (61.53%) and Jaundice (44.15%) frequency was higher in the patient. 38.46% patients were transfusion dependent. Mean hemoglobin and red cell indices were low in the HbS-D patients. HbF (Ranges; 2.3-4.6%) and HbA₂ (Ranges; 1.7-5.4%) were raised while HbA were <5%. Rest of Hb was HbS (<50%) and HbD (<50%). Details of clinical and hematological profiles are given in Figure 1 and TABLE 1 respectively. Patients were screened for four common alpha thalassemia deletions. Out of 13 patients; three

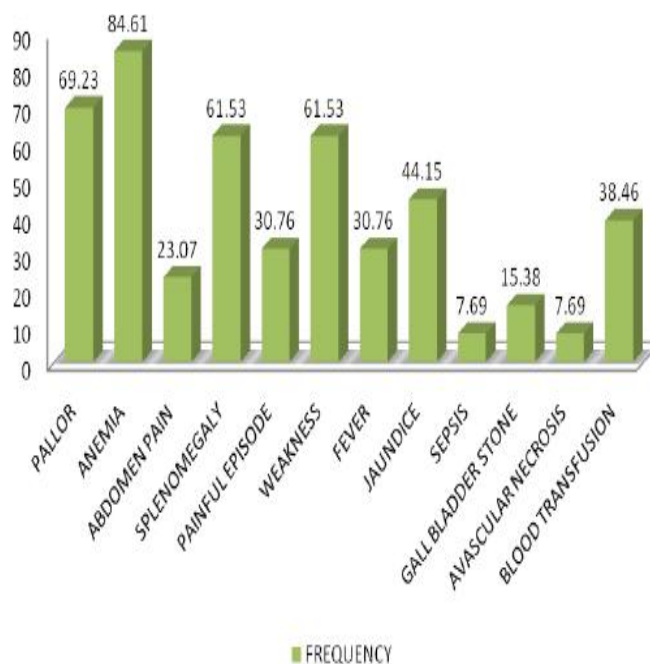


Figure 1 : Clinical feature of HbSD patients

TABLE 1 :Hematological profile of HbSD patients

Indices	Mean±SD
WBC Ths/μl	8.2±2
RBC millions/μl	3.2±0.4
HGB g/dl	7.2±2.6
HCT %	25.3±3.5
MCV fl	58.8±4.3
MCH pg	23.5±2.3
MCHC g/dl	21.5±4.1
PLT Ths/μl	141.2±76.3

were heterozygous and two were homozygous for the $\alpha^{3.7kb}$ deletions. HbD occurs in four forms; heterozygous HbD trait, HbD-thalassemia, HbS-D disease and the rare homozygous HbD disease, which is usually mild hemolytic anemia and mild to moderate splenomegaly^[12, 13]. HbD-Punjab is one of the most commonly observed abnormal hemoglobin variants worldwide, including Italy, Belgium, Austria and Turkey^[14-19]. HbD-Punjab occurs with greatest prevalence (2%) in Sikhs in Punjab, India, whereas Gujarat, the province in the west from where the case was reported, has a prevalence rate of 1%^[12]. Though HbD is not very uncommon in India, its homozygous form is very rare^[12, 13, 20]. Earlier studies from Pakistan, Iran, United Arab of Emirates and Mexico have shown that the clinical presentation of HbSD-disease cases is similar to that of patients with the severe form of sickle cell anemia^[21, 22]. On the other

Short Communication

hand, reports from India have shown variable clinical manifestations of Hb SD-disease^[8,23]. Though Hb D is not very uncommon in India, There is no detailed report of clinical and hematological profile of Hb D patients only few case reports have been reported^[24]. In our cases of hemoglobin sickle D patients showed the severity of disease with moderate hemolytic anemia. Most individuals with hemoglobin sickle D disease had jaundice, weakness, splenomegaly and painful episodes. Hemoglobin sickle D disease patient's red cell indices were suggestive like sickle cell anemia patients. Observation of the study conclude the co-existence of hemoglobin D with hemoglobin S produces clinically significant conditions like sickle cell anemia in Indian subjects.

ACKNOWLEDGEMENTS

Sincere thanks to technical staff of department of hematology AIIMS, for expert assistance.

Financial support

This study supported by Hematology Department AIIMS, New Delhi.

REFERENCES

- [1] P.Hellen, W.R.Best, R.B.Nelson, et al.; N.Engl.J. Med., **300**, 1001 (1979).
- [2] A.I.Chernoff; Hb.D.Syndromes.Blood, **13**, 116 (1958).
- [3] S.Dash; J.Ass.Phys.Ind., **35**, 874-5 (1987).
- [4] P.Sturgeon, H.A.Itano, W.R.Bergreu; The Interaction of Hemoglobin S with Hemoglobin D Blood, **10**, 389 (1955).
- [5] P.R.Mc Curdy, P.A.Lonkin, R.Cassey, H.Lehmann, D.E.Uddin, L.G.Dickson; Am.J.Med., **57**, 665 (1975).
- [6] H.P.Bunn, B.G.Forget; Hemoglobin. Molecular Genetic and Clinical Aspects, Philadelphia: WB Saunders Co., (1986).
- [7] S.Charache, W.H.Zinkham, J.D.Dicherman, et al.; Am.J.Med., **62**, 439 (1977).
- [8] S.Tyagi, N.Marwaha, V.Parmar, S.Basu; Ind.J. Hematol Blood Transf., **18**, 31-2 (2000).
- [9] E.Baysal, T.H.Huisman; Am.J.Hematol., **46(3)**, 208-13 (1994).
- [10] R.V.Shah, S.E.Eunice, S.Baidya, A.Srivastava, M.Chandy; Br.J.Haematol., **123(5)**, 942-7 (2003).
- [11] J.G.Chang, L.S.Lee, C.P.Lin, P.H.Chen, C.P.Chen; Blood., **78(3)**, 853-4 (1991).
- [12] J.N.Lukens; The Abnormal Hemoglobin's: General Principles. In. G.R.Lee, J.Foerster, J.Lukens, F.Paraskevas, J.P.Greer, G.M.Rodgers, Editors, Win robe's Clinical Hematology, Tenth Edition, Baltimore: Lippincott Williams & Wilkins, 1329-45 (1998).
- [13] S.Ozsoylu; Acta.Haematol., **43(6)**, 353-9 (1970).
- [14] H.J.Li, X.N.Zhao, F.Qin, et al.; Hum.Genet., **86(2)**, 231-5 (1990).
- [15] G.Fioretto, M.De Angioletti, L.Pagano, et al.; Hemoglobin., **17(1)**, 9-17 (1993).
- [16] H.Husquinet, M.T.Parent, S.Schoos-Barbette, et al.; Hemoglobin., **10(6)**, 587-92 (1986).
- [17] A.Lischka, A.Pollak, K.Bauer, H.Aschauer, G.Braunitzer; Hemoglobin., **8(4)**, 353-61 (1984).
- [18] E.O.Atalay, H.Koyuncu, B.Turgut, et al.; Hemoglobin., **29(4)**, 307-10 (2005).
- [19] S.Fucharoen, Y.Changtrakun, S.Surapot, G.Fucharoen, K.Sanchaisuriya; Hemoglobin., **26(3)**, 261-9 (2002).
- [20] F.Firkin, C.Chesterman, D.Penington, B.Rush; Disorders of Hemoglobin Structure and Synthesis, de Gruchi's Clinical Haematology in Medical Practice. 5th Edition, Oxford: Blackwell Science, 137-71 (1996).
- [21] F.J.Perea, M.Casas-Castaneda, A.R.Villalobos-Arambula, et al.; Hemoglobin., **23(3)**, 231-7 (1999).
- [22] S.El-Kalla, A.R.Mathews; Hemoglobin., **21(4)**, 369-75 (1997).
- [23] I.Panigrahi, S.Agarwal, P.Signal; Ind.J.Hematol. Blood Transf., **18**, 86-7 (2000).
- [24] R.C.Jain; Am.J.Clin.Pathol., **56(1)**, 40-2 (1971).